



**PRESENTING CLINICAL SIGNS**

History: Grade 2/6 murmur. Mild cough.

**DATE**

10/7/22

**ECHOCARDIOGRAPHIC FINDINGS**

2D, M-mode, and Doppler study.

**PERFORMED BY:**

Kelly Vazquez

**INTERPRETED BY**

Keith Blass, DVM,  
MS, DACVIM  
(Cardiology)

**PATIENT**

Coco Bella Forbes

Left atrial size is normal. The mitral valve leaflets are mildly thickened, and a mild jet of mitral regurgitation is present. Left ventricular dimensions are normal. Left ventricular systolic function is hyperdynamic. The aorta and aortic valve are normal. Right atrial and right ventricular dimensions are normal. The tricuspid valve appears normal, though trace tricuspid regurgitation is present. The pulmonary artery and pulmonic valve are normal. No shunting lesions are visualized. No pericardial effusion or cardiac masses are seen.

LA - 34.4 mm  
LVIDd - 30.1 mm  
LVIDs - 14.3 mm  
FS - 52%  
RA - 24.5 mm  
LVOT - 1.64 m/s  
RVOT - 1.09 m/s

**ASSESSMENT/RECOMMENDATIONS**

Degenerative mitral valve disease

**SPECIES**

Canine

**BREED**

Beagle

This examination demonstrates mild regurgitation of blood across Coco Bella's mitral valve resulting from degenerative valve disease. The hemodynamic effects of the regurgitation also appear to be mild, as Coco Bella does not have secondary dilation of either of her left heart chambers, and her left ventricular systolic function is well-preserved. As such, Coco Bella's mitral valve disease appears to be well-compensated, and it does not appear to be contributing to her mild cough.

No therapy is recommended at this stage of disease.

**SEX**

FS

**AGE**

9 y

**WEIGHT**

33 lb

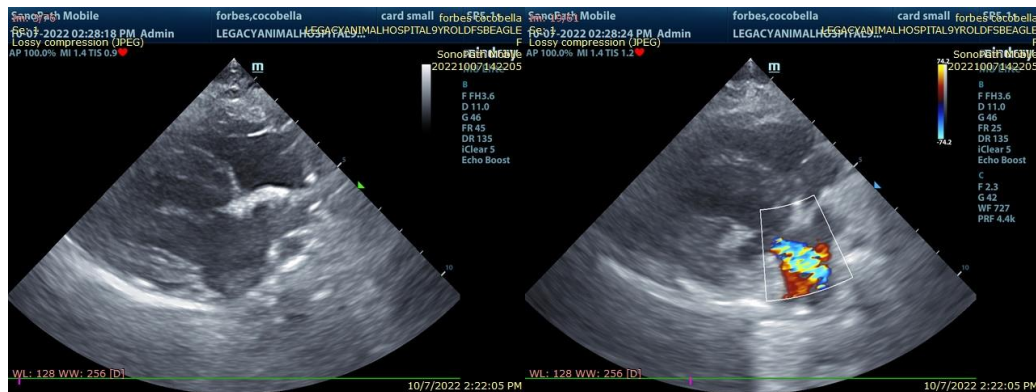
**HOSPITAL NAME**

Legacy AH

**REFERRING VET**

Dr. Potenzone

A recheck echocardiogram is recommended in ~6 months to monitor for disease progression.



The information and recommendations provided are based on the images presented by the referring veterinarian. No evaluation can be communicated regarding pathology that was not visible in the image/video clips provided.



Thank you for this referral. If the clinical or image interpretation does not parallel your findings or if I can be of any further assistance please contact me.

**DATE**

10/7/22

**Keith Blass, DVM, MS, DACVIM (Cardiology)**  
KeithBlass@gmail.com  
631-804-5754

**PERFORMED BY:**

Kelly Vazquez

**INTERPRETED BY**

Keith Blass, DVM,  
MS, DACVIM  
(Cardiology)

**PATIENT**

Coco Bella Forbes

**SPECIES**

Canine

**BREED**

Beagle

**SEX**

FS

**AGE**

9 y

**WEIGHT**

33 lb

**HOSPITAL NAME**

Legacy AH

**REFERRING VET**

Dr. Potenzzone